

Research Article**Effect of Methotrexate Therapy on Visual Functions****¹Memona Mohiuddin | ²Muhammad Sharjeel | ³Zeeshan Hameed**

¹College of Optometry and Allied Vision Sciences,
King Edward Medical University, Lahore, Pakistan.
Email: memonaklair2022@gmail.com

²Department of Ophthalmology, Gomal Medical
College, D.I.Khan, Pakistan,
Email: dr.sharjeel@gmail.com

³Postgraduate Resident Department of
Ophthalmology, Gujranwala Medical College, DHQ
Teaching Hospital Gujranwala, Pakistan.
Email: zeeshanhameed097@gmail.com
ORCID: <https://orcid.org/0000-0001-5718-8073>

Correspondence

Muhammad Sharjeel Assistant Professor Department
of Ophthalmology, Gomal Medical College,
D.I.Khan, Pakistan
Email: dr.sharjeel@gmail.com

Citation

Mohiuddin M, Sharjeel M, Hameed Z. Effect of
Methotrexate Therapy on Visual Functions. *Health
Sciences Journal*, 2022, 1(1),13-19.

ABSTRACT:

Aim: To find the effect of Methotrexate therapy on visual functions (visual acuity, contrast sensitivity, color vision, glare sensitivity, visual field) and ocular adnexa.

Study Design: Descriptive cross-sectional study

Place and Duration: College of Ophthalmology and Allied Vision Sciences (COAVS), Mayo Hospital Lahore from September 2016 to November 2016.

Material and Methods: A total of 30 patients having psoriasis and rheumatoid arthritis taking Methotrexate therapy with different doses and different durations were questioned through a specified Performa and then examined for changes in ocular adnexa and visual functions. Results were saved on Excel Sheets and analyzed with SPSS v.25.0.

Results: Patients taking Methotrexate therapy were found to have affected visual functions with color vision and visual field being more affected as compared to other visual functions. Dosage significantly affects color vision ($p=.002$) and visual field ($p=.001$). While in terms of duration, it was analyzed that there is significant relation ($p=.006$) between duration and the color vision and same was with the visual field ($p=.001$).

Conclusion: Methotrexate therapy has less effect on visual acuity, contrast sensitivity, glare sensitivity and ocular adnexa. However, color vision and visual field were affected due to Methotrexate therapy, and neurological visual field defects occur due to long term (1-2 years) therapy.

KEYWORDS

Methotrexate, Ocular Toxicity, Visual Functions, Color Vision, Visual Fields.

1 | INTRODUCTION

Methotrexate (MTX) is an antimetabolite and antifolate drug widely used in treatment of psoriasis, rheumatoid arthritis, psoriatic arthritis, autoimmune diseases and for the initiation and maintenance of abatement in Crohn's disease.¹⁻⁴ It can be given as monotherapy or in combination with other drugs made up of oral agents and newer biological agents. Methotrexate is also effective in the treatment of malignant and non-malignant inflammatory diseases.⁵ It is prescribed as a first line treatment in active rheumatoid patients.⁶ It can be given orally or an injectable form.⁷ However, it also plays a major role in the therapy of cancer, ectopic pregnancy and for induction of medical abortion.^{8,9} Certain side effects of Methotrexate are hepatotoxicity, ulcerative stomatitis, neurologic damage and low white blood cell count and thus leading to infection, nausea, abdominal pain, fatigue, fever, dizziness, acute pneumonitis, rarely pulmonary fibrosis and kidney failure while most common side effects are gastrointestinal upset, oral ulceration and neutropenia.¹⁰ When this drug crosses blood brain barrier and damage neurons in cerebral cortex, neurotoxicity occurs. When MTX is administered in high doses, it also causes cutaneous and lung toxicity.¹¹ It has an injurious effect on memory loss. To a great concern, it also causes potential visual and sight threatening complications.¹²

Ocular toxicities caused by Methotrexate include periorbital edema, ocular pain, blurred vision, photophobia, conjunctivitis, blepharitis, decreased reflex tear secretion and Non-arteritic ischemic optic neuropathy. Optic neuropathy occurs due to folate deficiency that may be nutritional or genetic.¹³ Central scotoma with an unremarkable optic disc and toxic optic neuropathy is also found after long-term treatment with methotrexate.¹⁴ Cotton wool spots are also documented as the presenting feature of systemic MTX toxicity.¹⁵ Methotrexate when administered intravenously causes conjunctivitis, blurred vision and periorbital edema at high doses and when administered intrathecal causes inter-nuclear ophthalmoplegia. Isolated sixth nerve palsy is also included in an atypical complication of this drug.¹⁶ Neuro-ophthalmic toxicities such as optic nerve demyelization, optic neuropathy, retinal pigmentary mottling, myelopathy and aseptic meningitis occur due to the high doses of Methotrexate when given through intrathecal route.^{17,18} Ocular complications could be treated or prevented, if detected or diagnosed on time. Therefore, a basic ophthalmic examination for patients receiving Methotrexate therapy should be done to get early diagnosis regarding any ocular issue. For the assessment of ocular health, we can assess visual functions.

1.1 | Aims & Objectives

1. To detect the detrimental fluctuations occurring in visual functions in patients receiving Methotrexate therapy and correlate these fluctuations with dosage and duration.
2. To aware the public if potential sight-threatening complications of Methotrexate found.

2 | MATERIAL AND METHODS

2.1 | Research Design

It was a descriptive cross-sectional study.

2.2 | Population & Sampling

The study was conducted at College of Ophthalmology and Allied Vision Sciences (COAVS), Mayo Hospital Lahore from September 2016 to November 2016.

2.3 | Data Collection

All patients taking MTX therapy from 3 months to 2 years were included while patients having any other systemic disease contributing to visual dysfunction were excluded. The tools used for assessing visual functions were Log

Marchart for recording vision, Pelli Robson chart for contrast sensitivity, Farnsworth D15 chart for color vision, Humphrey automated visual field analyzer for recording visual field and slit lampbimicroscope was used for assessment of ocular adnexa. Data was collected through a self-designed Performa. 30 patients were examined in the COAVS, Mayo Hospital. The patients using MTX were taken from the Orthopedics and Dermatology ward and examined in Eye ward Mayo hospital Lahore. Firstly, the consent was taken and all the tests were explained to the patient. Then the patients were clinically examined.

2.4 | Analysis Technique

Data was analyzed in SPSS version 25.0. Non probability purposive sampling method was used. Different tables were made to represent the frequencies and relation between (Dosage, Duration) and visual functions.

3 | RESULTS

30 patients were included in this study having age range between 18 years to 70 years with mean age of 36.70±12.14 years. There were 50% patients who received 5mg dosage, 38.67% patients with 2.5mg and 6.667% patients with 2ml and 5ml dosage in this study. 40% patients were taking therapy from 1.5 to 2 years, 36.67% patients from 0.5-1 year, and 23.33% patients from 2- 3 months duration. Firstly, the relation between dosage and visual functions (visual acuity, contrast sensitivity, color vision, glare sensitivity, visual field) and ocular adnexa was seen in which there was no statistically significant difference between dosage and visual functions and adnexa. But color vision and visual fields were found to be affected by dosage as shown in tables below.

TABLE 1 Dose vs. Color Vision

		Dosage				Total
		2.5 mg	5 mg	2 ml	5 ml	
Color Vision	Normal	2	5	1	0	8
	Protane	2	5	1	2	10
	Deutane	5	3	0	0	8
	Tritane	2	2	0	0	4
Total		11	15	2	2	30

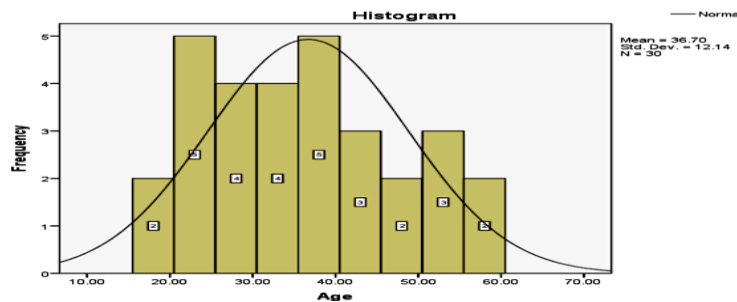


FIGURE1: Distribution of Age

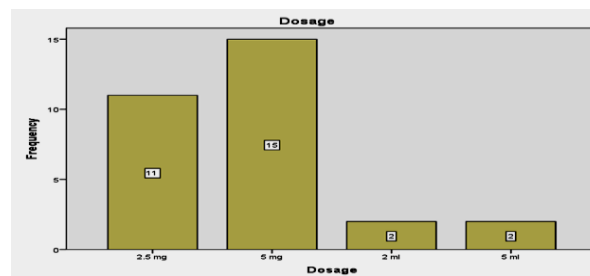


FIGURE 2: Distribution of Dosage

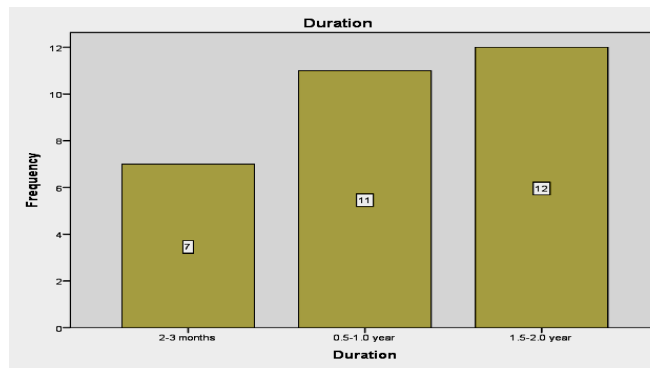


FIGURE 3: Distribution of Duration

Table # 1 shows that the majority of patients have Protane, Deutane and Tritane defects and few of the patients have normal color vision. As far as dosage concerns, 2.5 and 5 mg dosage affects color vision in more patients as compare to other dosages. However, the difference is statistically significant, One Way analysis of variances (ANOVA) $F(2, 27) = 8.241$ with a P value of .002 which is < 0.05 meaning that there is marked difference between dosages of Methotrexate therapy and color vision.

TABLE 2 Dose vs. Visual Fields

		Dosage				Total
		2.5 mg	5 mg	2 ml	5 ml	
Visual field	Affected	4	12	2	2	20
	Not affected	7	3	0	0	10
Total		11	15	2	2	30

Table # 2 shows that the majority of patients have affected visual field taking 2.5 and 5 mg dosage. However, the difference is statistically significant, One Way analysis of variances (ANOVA) $F(2, 27) = 21.441$ with a P value of .001 which is < 0.05 meaning that there is marked difference between dosages of Methotrexate therapy and visual field. Secondly, the relationship between duration and visual functions was seen in which there was no statistically significant difference between duration and (visual acuity, contrast sensitivity, glare sensitivity), adnexa. But color vision and visual field were found to be affected by increasing duration i.e. shown in the tables below.

TABLE 3 Duration Vs Color Vision

Variable	Category	Duration			Total
		2-3 months	0.5-1.0 year	1.5-2.0 year	
Color Vision	Normal	3	4	1	8
	Protane	1	7	2	10
	Deutane	3	0	5	8
	Tritane	0	0	4	4
Total		7	11	12	30

Table # 3 shows that the majority of patients have color vision defect taking therapy from 1-2 years as compare to patients taking therapy from 2-3 months. The Pearson Chi square value is 18.015 at degree of freedom 6, giving the p value of .006 which means that there is statistically significant relationship between duration and color vision.

Table # 4 shows that visual field is affected in patients taking therapy from 1-2 year. As a whole majority of patients have affected visual field and minority of patients have not affected visual field. The Pearson Chi square value is

18.409 at degree of freedom 2, giving the p value of .001 which means that there is statistically significant relationship between duration and visual field.

TABLE 4 Duration Vs Visual Fields

Variable	Category	Duration			Total
		2-3 months	0.5-1.0 year	1.5-2.0 year	
Visual field	Affected	0	10	10	20
	Not Affected	7	1	2	10
	Total	7	11	12	30

4 | DISCUSSION

Numerous systemic drugs produce adverse effects that involve the eye. The eye because of its rich blood supply and relatively small mass exhibits an unusually high susceptibility to toxic substances.¹⁹ Drug molecules present in systemic circulation can reach the ocular structures by way of the uveal or retinal vasculature.²⁰ The clinicians all over the globe are agreed about the side effects of drugs on the eye. Many of the drugs have adverse effects on the body organs in the same way they can also affect the eye. So this is essential to accurately evaluate visual functions as this will help in early diagnosis of conditions and also monitor the diseases like glaucoma, cataract etc. As with other drugs, Methotrexate is not without ocular side effects.²¹ Balachandran C and his colleagues did a study to evaluate the adverse effects of Methotrexate on the eye. In this study it was seen that Methotrexate inhibits folate metabolism that results in folate defalcation which leads to optic neuropathy. Methotrexate induced optic neuropathy involves pathogenesis of demyelinating optic neuropathy. So in this study, Toxic optic neuropathy caused by Methotrexate was observed.²²

Another study in which a female patient suffering from psoriatic arthritis was given Methotrexate therapy for a long time. The acute attack of the central visual field defect occurs in her right eye that gets worse within one year. When the MTX therapy was stopped, after six weeks her visual field defects started improving. It was concluded that long term treatment with MTX can result in unilateral central visual field defect in a patient taking MTX therapy even with folic acid supplement.¹¹ This was also proposed by Adhikari et al. in their study done on CNS lymphoma treated with methotrexate.²³

In the present study patients taking Methotrexate therapy were found to have affected visual function. This was observed that a large number of patients have Protane, Deutane and Tritane color vision deficiencies. 2.5 and 5 mg dosage affects color vision in more patients as compared to other dosages. So, Dosage of Methotrexate therapy significantly affects ($p = 0.002$) color vision causing Protanopia, Deutranopia and Tritanopia. Clare et al. also described similar patterns of defective color vision in patients taking 2.5mg dosage 3 times a week.²⁴

In the same way, the visual field is also affected significantly ($p=0.001$) by the (2.5 and 5 mg) dosage of Methotrexate therapy. Although 17(56.7%) patients have defective glare sensitivity but in terms of dosage, there was no statistically significant relationship between dosage and Methotrexate therapy. As far as the duration is concerned, therapy taken for 1-2 years has more effects as compared to therapy taken from 2-3 months. So in terms of duration, Methotrexate therapy significantly affects ($p=.006$) color vision and visual field ($p=.001$). It was concluded that as compared to the other visual functions color vision and visual field were affected more. This was also supported by Zahar et al. in his work.²⁵ Patients show scotomas and visual field defects (neurological) due to long term (1-2 year) use of Methotrexate therapy.

There's very limited data showing that Methotrexate causes color vision defects. As in other studies showing visual field defects with Methotrexate, our study also reveals a strong association between visual field defects and Methotrexate therapy. However, there was no statistically significant association between (dosage & duration) of

Methotrexate therapy and visual status, contrast sensitivity, glare sensitivity and adnexa.

5 | LIMITATIONS AND FUTURE DIRECTIONS

This study's main limitation is small sample size and even smaller duration. To have a greater future impact, a vast multicenter study with more sample size needs to be conducted. Moreover, only subjective aspects of visual functions were assessed in this study, ignoring objective findings like fundus examination and other clinical tests of optic nerve function. This needs to be addressed in future works. However, despite its limitations, this study might prove to be guide for physicians prescribing MTX to keep an eye on ocular side effects of the drug during its course of prescription and timely referral to ophthalmologist for subsequent management.

6 | CONCLUSION

Methotrexate is a drug known to cause visual function deterioration in the long term but our paper further elaborated that which functions are more affected and which are less affected. It was concluded that as compared to other visual functions (visual status, contrast sensitivity, glare sensitivity and adnexa) color vision and visual field were affected due to Methotrexate therapy. This study shows more deleterious effects on visual field and color vision with 1-2 years' duration and (2.5mg, 5mg) dosage.

Ethical Approval

No ethical approval was needed for this study.

Conflict of Interests

None declared.

Funding

None

REFERENCES

1. Katturajan R, Vijayalakshmi S, Rasool M, Prince SE. Molecular toxicity of methotrexate in rheumatoid arthritis treatment: A novel perspective and therapeutic implications. *Toxicology*. 2021 Sep;461:152909.
2. Hannoodee M, Mittal M. Methotrexate. InStatPearls [Internet] 2022 Jan 20. StatPearls Publishing.
3. García-González CM, Baker J. Treatment of early rheumatoid arthritis: methotrexate and beyond. *Curr Opin Pharmacol*. 2022 Jun;64:102227.
4. Aickara D, Bashyam AM, Pichardo RO, Feldman SR. Topical methotrexate in dermatology: A review of the literature. *J Dermatolog Treat*. 2022 Jan;33(1):512-7.
5. Conway R, Low C, Coughlan RJ, O'Donnell MJ, Carey JJ. Methotrexate use and risk of lung disease in psoriasis, psoriatic arthritis, and inflammatory bowel disease: systematic literature review and meta-analysis of randomized controlled trials. *BMJ-BRIT MED J*. 2015; 350(1269):1-4.
6. Curtis JR, Bykerk VP, Aassi M, Schiff M. Adherence and persistence with methotrexate in rheumatoid arthritis: A systematic review. *J. Rheumatol*. 2016;43(11):1997-2009.
7. Saif S, Kakalia S, Kitchlew R, Khan HA, Fida S, Siddique M. Role of ondansetron in reducing methotrexate intolerance in patients with inflammatory arthritis. *Age*. 2022 Oct ;30(23):12-7.
8. Doulah A, Shushtarian SM. Probable toxic effect of methotrexate on visual pathway using visual evoked potential. *Indian J Appl Res*. 2016; 6(2):499-500.
9. Clowse ME, Saag KG. Unintended consequences of scotus abortion decision for patients with rheumatic diseases. *Ann. Intern. Med*. 2022 Sep;175(9):1328-9.
10. Ogdie A, Maksabedian Hernandez EJ, Shaw Y, Stolshek B, Michaud K. Side effects of methotrexate and tumor necrosis factor inhibitors: differences in tolerability among patients with psoriatic arthritis and rheumatoid arthritis. *ACR Open Rheumat*. 2022 Aug 15.
11. Kaymak E, Karabulut D, Öztürk E, Akin At, Kuloğlu N, Yakan B. Vitamin B12 alleviates methotrexate-induced lung injury in rat: a histopathological, immunohistochemical, and biochemical study. *Turk HijTeczBiyolDerg* . 2022 Jan;79(1):81-92.

12. Hirshberg B, Muszkat M, Schlesinger O, Rubinow A. Safety of low dose methotrexate in elderly patients with rheumatoid arthritis. *Postgrad. Med. J.* 2000;76(902):787-9.
13. Sevimli N, Karadağ R, Madenci E, Bayramlar H, Arslan P, Ocal A et al. Ocular surface findings in patients with rheumatoid arthritis under methotrexate or biological agent therapy, *CutanOculToxicol* 2017;36(1):48-51
14. Peponis V, Kyttaris VC, Chalkiadakis SE, Bonovas S, Sitaras NM. Ocular side effects of Anti-rheumatic medications: what a rheumatologist should know. *Lupus.* 2010; 19(6):675-682.
15. Sbeity ZH, Baydoun L, Schmidt S, Loeffler KU. Visual field changes in methotrexate therapy. Case report and review of the literature. *J Med Liban.* 2006; 54(3):164-167.
16. Klemencic S. Cotton wool spots as an indicator of methotrexate-induced blood dyscrasia. *Optometry.* 2010; 81(4):177-80.
17. Greenblatt D, Sheth N, Teixeira F, Akland K. Isolated sixth nerve palsy following low dose oral methotrexate. *Dermatol online J.* 2017; 13(4):19.
18. Sotoudehmanesh R, Anvari B, Akhlaghi K, Shahranein S, Kollahdoozan S. Methotrexate hepatotoxicity in patients with rheumatoid arthritis. *Middle East J. Dig. Dis.* 2010;2(2):104-9.
19. DeBuc DC, Rege A, Smiddy WE. Use of xycam ri for noninvasive visualization and analysis of retinal blood flow dynamics during clinical investigations. *Expert Rev. Med. Devices.* 2021 Mar;18(3):225-37.
20. Rousou C, Schuurmans CC, Urtti A, Mastrobattista E, Storm G, Moonen C, Kaarniranta K, Deckers R. Ultrasound and microbubbles for the treatment of ocular diseases: From preclinical research towards clinical application. *Pharmaceutics.* 2021 Oct;13(11):1782.
21. Ali A, Shah AA, Jeang LJ, Fallgatter KS, George TJ, DeRemer DL. Emergence of ocular toxicities associated with novel anticancer therapeutics: What the oncologist needs to know. *Cancer Treat. Rev.* 2022 Mar;102376.
22. Balachandran C, McCluskey PJ, Champion GD, Halmagyi GM. Methotrexate induced optic neuropathy. *ClinExpOphthalmol.* 2002; 30(6):440-1.
23. Adhikari N, Biswas A, Bakhshi S, Khanna G, Suri V. A rare case of paediatric primary central nervous system lymphoma treated with high-dose methotrexate and rituximab-based chemo immune therapy and whole brain radiotherapy followed by tumour bed boost with three-dimensional conformal radiation technique. *Child's Nervous System.* 2018 Sep;34(9):1777-83.
24. Clare G, Colley S, Kennett R, Elston JS. Reversible optic neuropathy associated with low-dose methotrexate therapy. *J. Neuro-Ophthalmol.* 2005 Jun;25(2):109-12.
25. Zahar H S, Lamis B, Stephan S, Karin U L. Visual field changes in methotrexate therapy case report and review of the literature. *J. Med Liban.* 2006; 164-167.